Pancreatic Cysts: More Than Just a One Year Follow-up MRI

DARIUS A. JAHANN, MD
Assistant Professor of Medicine
Section on Gastroenterology and Hepatology
Atrium Health Wake Forest Baptist

Atrium Health
Wake Forest Baptist

Joint CME/MOC Providership

Disclosures

- No relevant financial disclosures

Learning Objectives

1. Classify pancreatic cystic neoplasms.
2. Review the features of the most common pancreatic cystic neoplasms.
3. Understand the indications for EUS in the diagnosis of pancreatic cystic neoplasms
4. Discuss the high risk criteria which would warrant referral to a pancreatic specialty center
5. Appreciate when to not worry about a pancreatic cystic neoplasm.

Epidemiology

Aging Population

+

Better quality cross-sectional imaging

=

- **Increased detection of asymptomatic pancreatic cysts**
- **True prevalence is unclear**
- **2803 pts (2010): 2.4%**
- **1077 pts (2018): 49.1%**
- **Most are small. 0.8% are >2 cm**

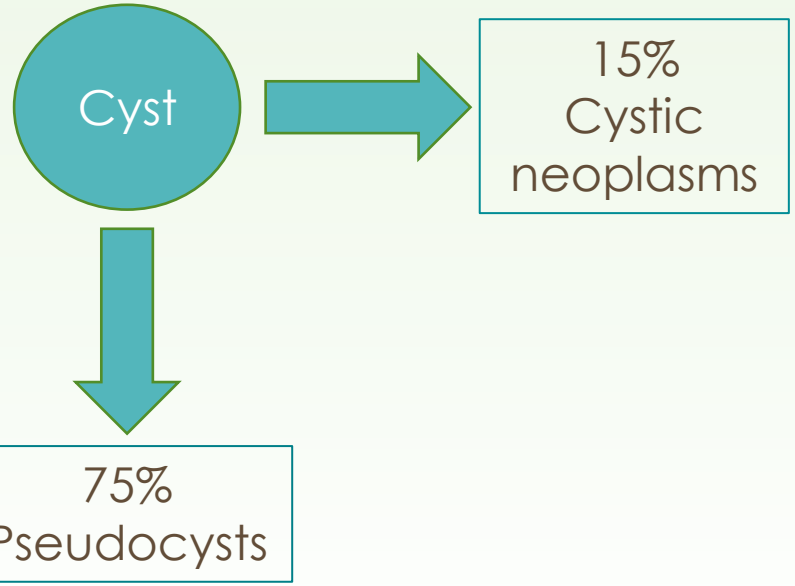

Jong et al. Clin Gastro Hep 2010; 8(9):806-811.
Kromrey et al. Gut 2018; 67(1):138-145..

Case 1

50-year-old man with intermittent abdominal pain and elevated liver enzymes. You are concerned about common bile duct stone and order an MRI/MRCP.

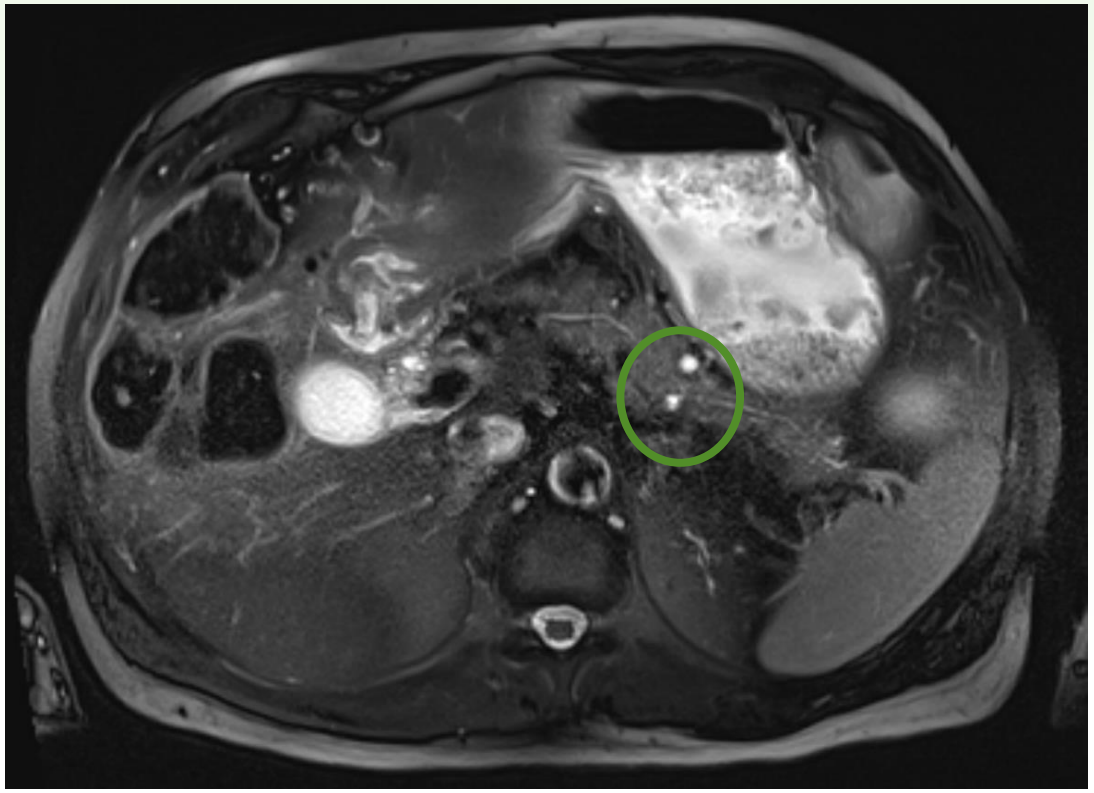

- Radiology Impression: "Small cystic lesions in the body of the pancreas, likely small intraductal papillary mucinous neoplasms. Recommend follow-up in 1 year."
- Things the radiologist probably does not know:
  - Symptoms
  - Clinical history
  - Risk factors for pancreatic cancer
  - Anything going on outside of their reading room

Questions for Self-Reflection

- What type of cyst is this?
- What is its malignant potential?
- Does this patient have alarm symptoms?
- Does this patient have risk factors for pancreatic cancer?
- Should I repeat imaging? What type? How soon?
- Do they have any prior imaging to compare it to?
- Does the patient need referral to a tertiary care center?
- Does the patient need an Endoscopic Ultrasound (EUS)?
- Does the patient need a referral to a surgeon?

Types of Pancreatic Cysts

Non-Neoplastic (~85%)

- Simple Cyst
- Lymphoepithelial Cyst
- Mucinous nonneoplastic cyst

Neoplastic (~15%)

- ***Intraductal Papillary Mucinous Neoplasm***
- ***Mucinous Cystic Neoplasm***
- Serous Cystadenoma
- Solid pseudopapillary neoplasm
- Cystic pancreatic neuroendocrine tumor
- Acinar-cell Cystadenocarcinoma
- Pancreatic Ductal Adenocarcinoma etc.

Differentiating Pancreatic Cysts

- Clinical Context: Age, Gender, Co-morbidities, Symptoms
- Imaging Morphology (Cross-sectional imaging or EUS)
- Communication with the pancreatic duct
- Fluid analysis

Cross-Sectional Imaging in Cysts

- Good initial testing for detection + characterization
- Diagnostic accuracy 20% to 83%
- 40% of serous and mucinous lesions are misdiagnosed as pseudocysts
- Multicenter study 398 patients. Accurate preop dx:
  - 20% serous cystadenoma
  - 30% mucinous cystadenoma
  - 29% mucinous cystadenocarcinoma
- Less accurate in cysts < 3 cm
- MRI superior to CT in diagnosing cysts and defining PD anatomy

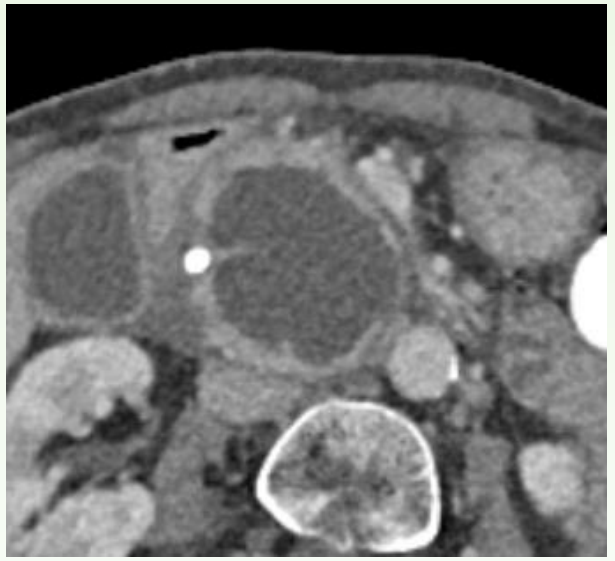

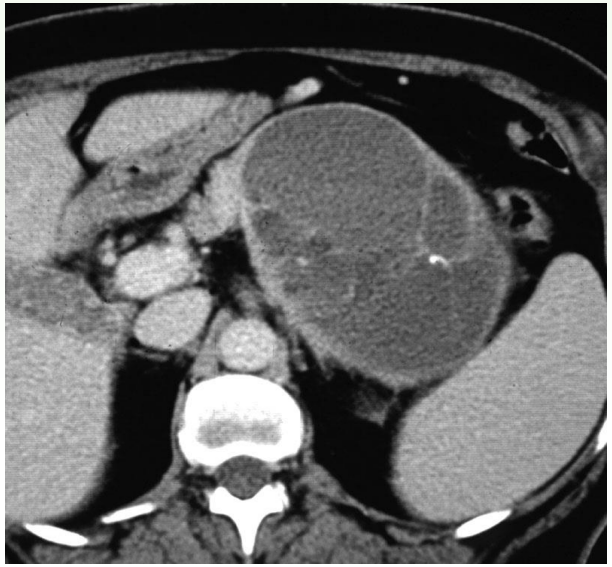

Le Borgne et al. Ann Surg 1999; 230:152-61.

Case #1

71-year-old woman with a PMH of multiple myeloma and a renal mass with plans for nephrectomy. During workup for that mass she was found to have a "pancreatic lesion" on CT.

MRI Abdomen W/ W/out:

"Multicystic lesion in head/uncinated 3.1 cm x 2.3 cm x 1.8 cm with a concerning enhancing nodule"

The patient was referred for EUS



Case #1: EUS

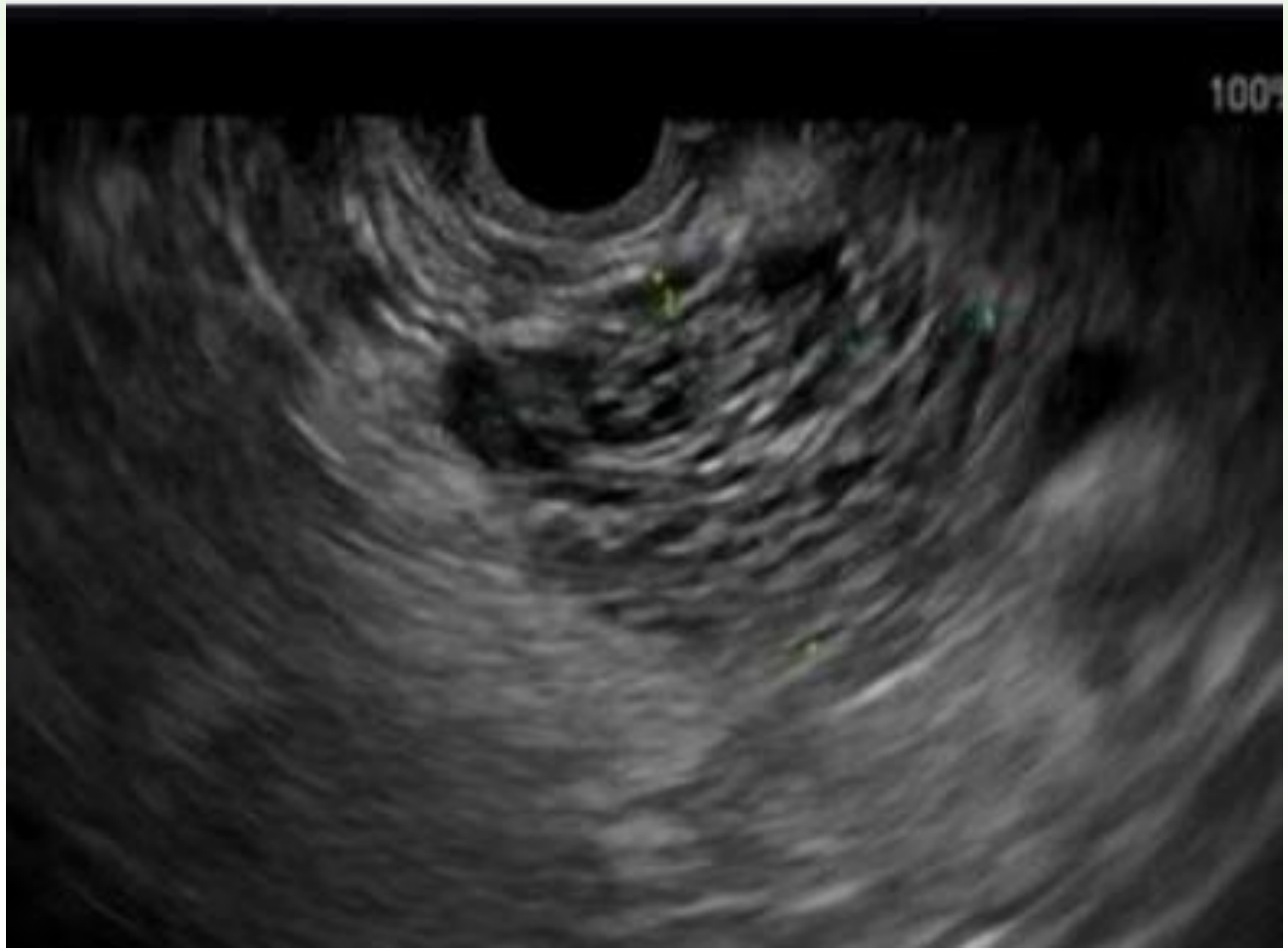

Serous Cystadenoma (Microcystic)

Benign

Non-mucinous

Diagnosed by EUS appearance

Risk of CA: 0.1%

Females >> Males

No connection to main PD

Slow growing

No surveillance necessary

If symptomatic -> surgical resection

Characterizing Cysts on EUS

EUS Morphology

- ***Size***
- ***Echotexture***
- ***Septation***
- ***Wall Thickness***
- ***Nodules***
- ***Associated mass***
- ***Communication with Pancreatic Duct***

- Diagnosis of malignant/pre-malignant lesions: ~82 to 96%
- Differentiating mucinous from non-mucinous: ~51%
- Differentiating neoplastic from non-neoplastic: ~50 to 94%
- Most of the time, this is sufficient and FNA not necessary

Case #2

73-year-old female with T2DM, HTN, OSA on CPAP who had a lumbar Xray demonstrating left upper quadrant calcifications. CT abdomen w/contrast was performed:

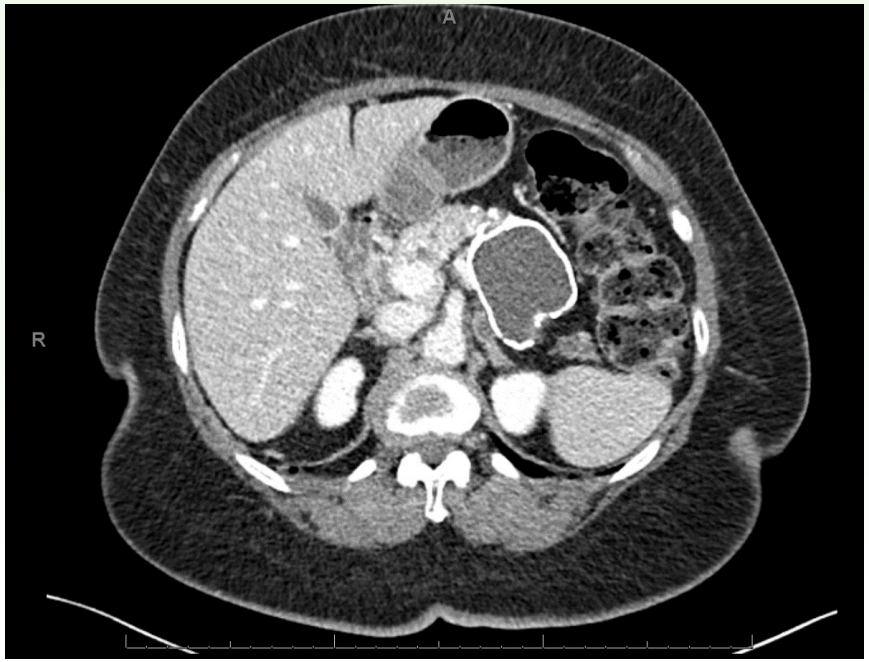

Pancreatic body cyst, up to 5.5 cm. Upstream pancreatic atrophy and ductal dilation to 1.1 cm. Scattered parenchymal calcifications. Unclear if this represents mucinous cystic neoplasm, mixed-type intraductal papillary mucinous neoplasm, or pseudocyst.

Case #2: EUS-FNA

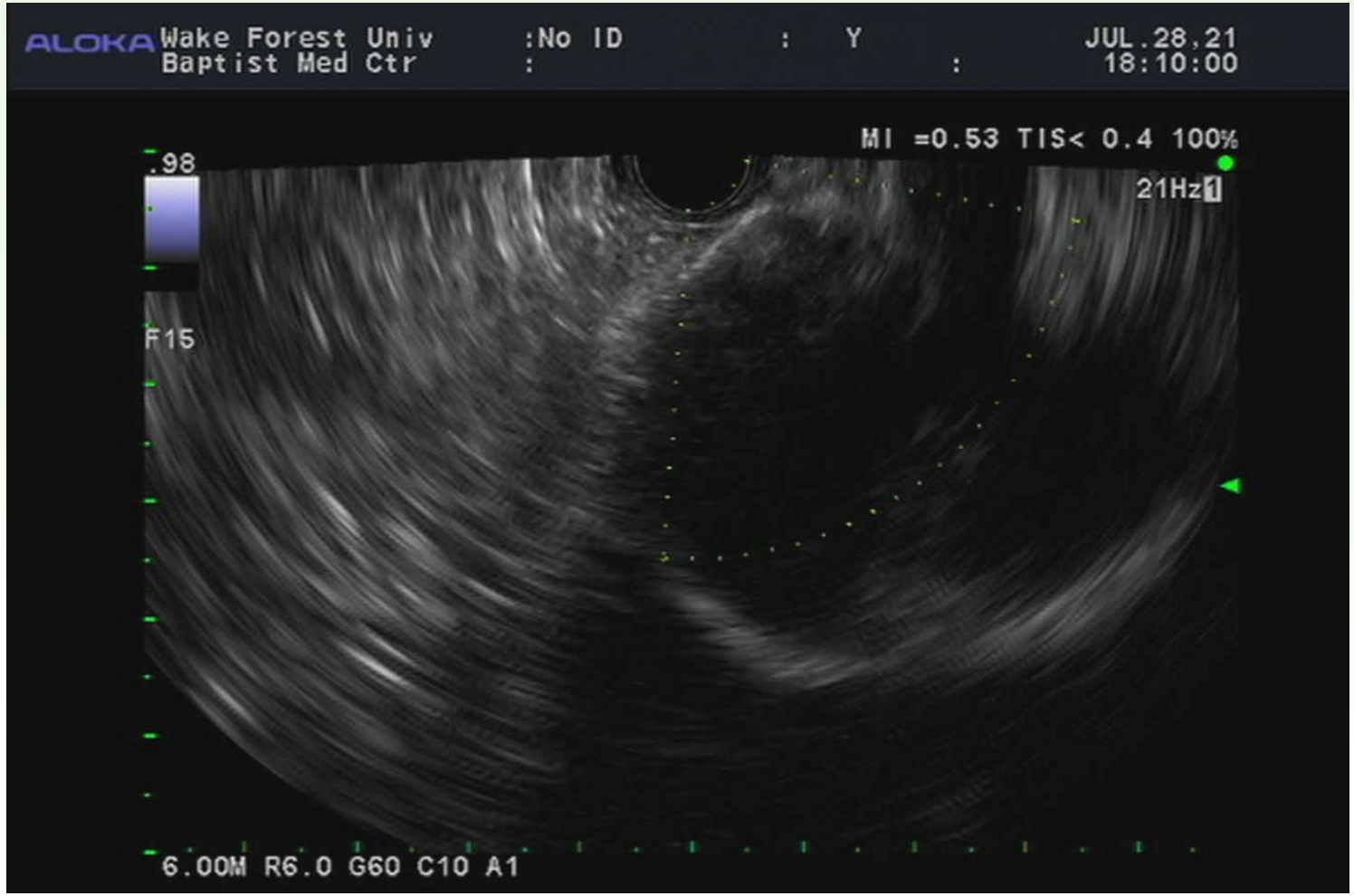

55 mm x 45 mm anechoic, unilocular cyst. No intramural nodules. No communication with PD. No associated masses. Findings of chronic pancreatitis were also noted

Because of its size and uncertainty about the diagnosis, FNA was performed

Case #2

Info from EUS-FNA of cyst fluid:

1. **CEA** > 192: mucinous
2. **Amylase**: connection to pancreas duct
3. **Cytology**: microscopic evaluation

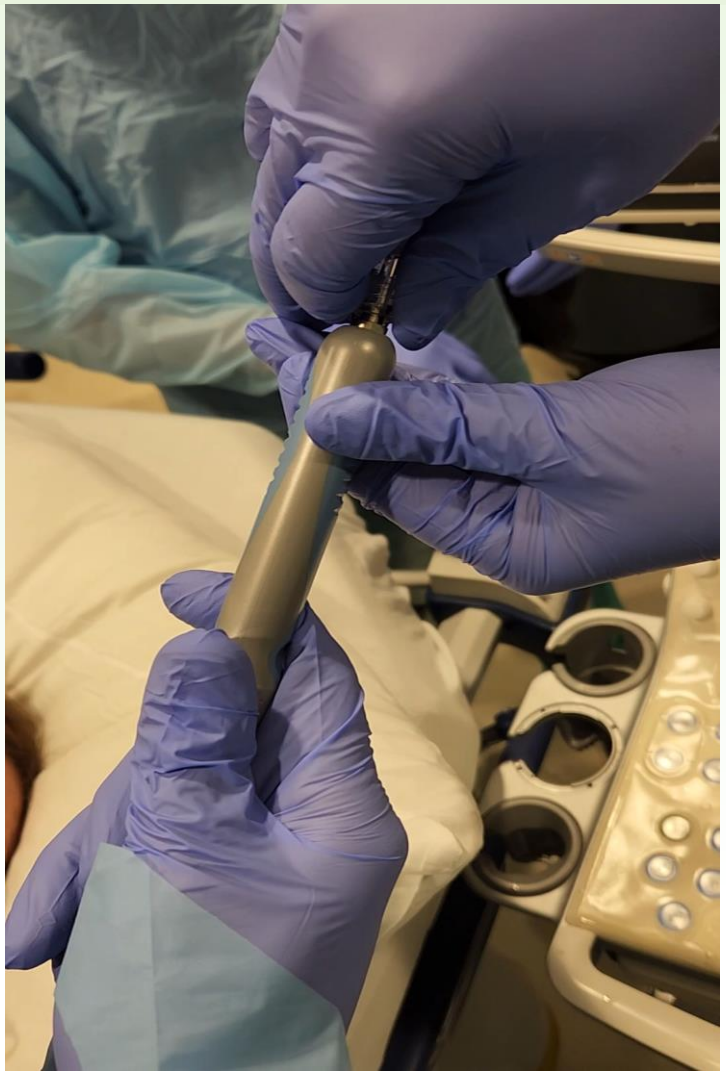

CEA: 1.8 ↓
Amylase: 411 ↑
Cytology: Negative

EUS-FNA: When Is It Helpful?

- Safely obtain cyst fluid for analysis
- When not sure about the diagnosis and results would change management
- Evaluate for adenocarcinoma if high risk features are present
- For larger cysts
- Visual clues immediately after aspiration

	SCN	IPMN	MCN	PSEUDOCYST
CEA	LOW	HIGH	HIGH	LOW
MUCIN	NO	YES	YES	NO
AMYLASE	LOW	HIGH/VARIABLE	VARIABLE	HIGH

Photo Credit: Vanessa Shami, MD

Intraductal Papillary Mucinous Neoplasm (IPMN)

- Mucin-producing
- Communicate with the main PD
- Men > Women. Mid 60s
- Premalignant, but natural history regarding progression to CA not well characterized
- This constitutes the majority of incidentally-discovered pancreatic cysts
- Singular (60%) or multifocal (40%). No evidence that the risk of malignant transformation is higher with multiple cysts
- 3 main categories based on the type of PD they involve

IPMN: Types

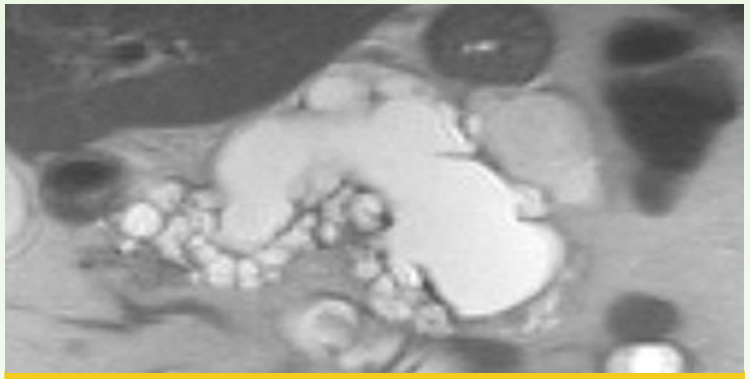

Main duct IPMN (MD-IPMN)

- Least common type
- Segmental or diffuse dilation of PD without other causes
- Highest risk of malignancy (38-68% harbor HGD or PC in resected specimens)
- Can secrete mucin at the major papilla, rarely leading to pancreatitis
- Considering of surgery depending on the PD diameter

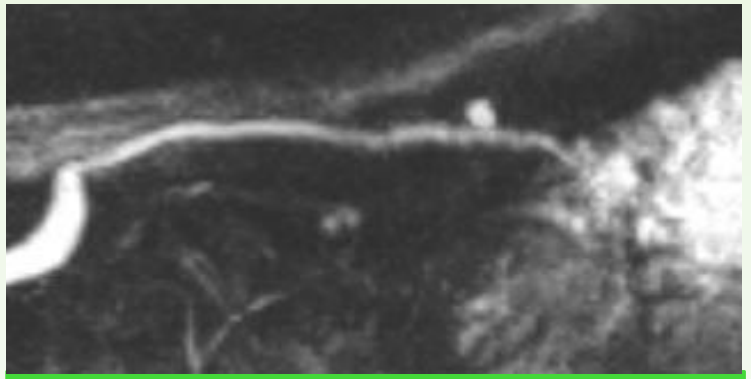

Branch duct IPMN (BD-IPMN)

- Most common
- Communicates with main PD. No dilation
- Malignancy risk less than MD-IPMN
- Several guidelines for management

Mixed IPMN

- Satisfy both of the above: PD dilation *AND* Cyst separate from the PD

Stark et al. JAMA 2016;315:1882-93.

ALOKA
:No ID
NOV 21,22
12:16:27
MI = 1.1 TIS< 0.4 100% 62Hz
7.50M R4.0 Q50 D73 A3
17:LINEAR140new2 Probe:Lin-140
AIP

Video 2

Guidelines on management of pancreatic cystic neoplasms

Guideline Differentiation

Guidelines differ on:
- Surveillance intervals
- When to stop surveillance
- When to refer patient to surgery

2017 International Consensus Guidelines

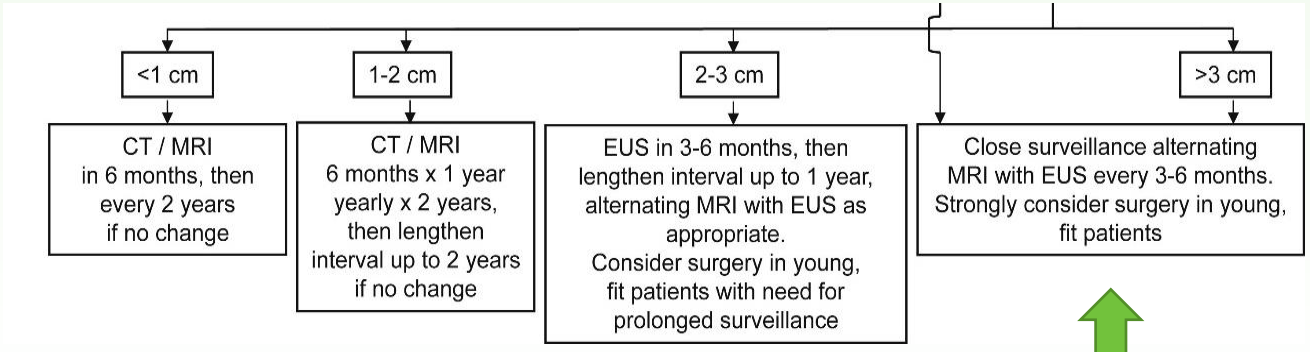

Alternate MRI with EUS every 3-6 mo.
Surgery in young pts.

2018 American College of Gastroenterology Guidelines

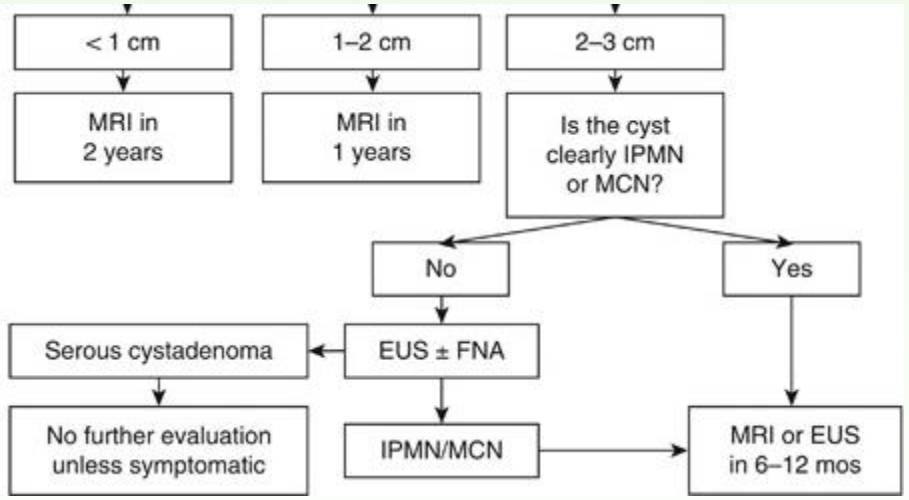

MRI or EUS in 6-12 mo.

Practical Approach to Cysts: Clinic

- **Symptoms**
  - Abdominal pain
  - Back/flank pain
  - Early satiety, N/V
  - Weight loss
  - Jaundice
- **Recent events**
  - Pancreatitis
  - Diabetes
- **Past Medical History**
  - Chronic pancreatitis
  - Genetic disorder
  - Major co-morbidities
- **Family history**
  - Pancreatic cancer
  - Pancreatitis
- **High quality imaging (MRI > CT)**
- **Prior imaging for comparison**

Case #3

71-year-old man with hx of CAD, CVA on Xarelto.

Nov 2022: Admitted with acute interstitial pancreatitis. No cause identified.

CT A/P: 2.0 cm cystic lesion at the neck of the pancreas.

MRI: Swelling and edema from acute pancreatitis. 2.0 cm pseudocyst in the pancreatic neck. No CBD/PD dilation.

4 weeks after admission, patient underwent EUS.

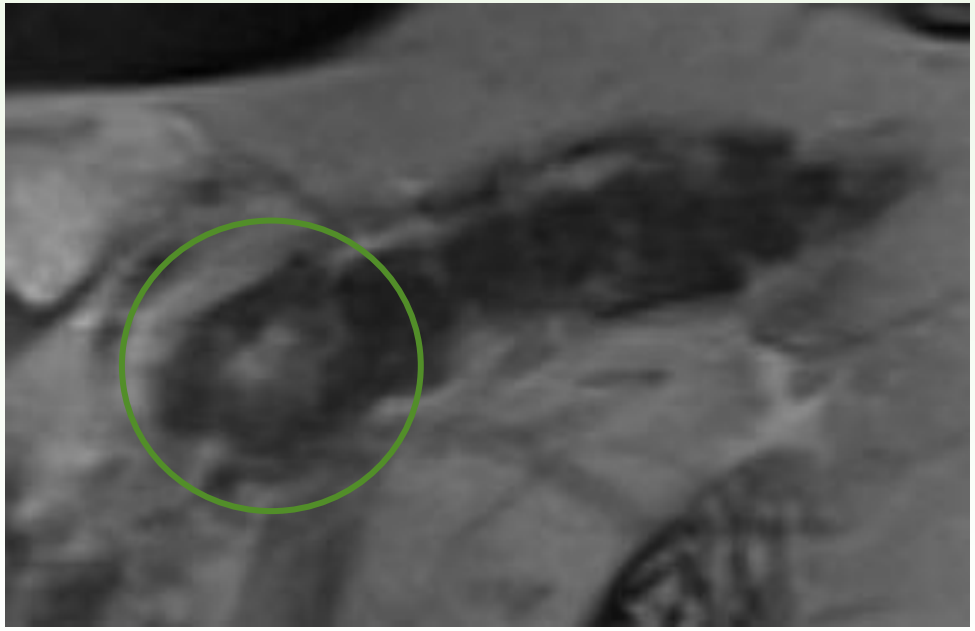

EUS 12/23/22

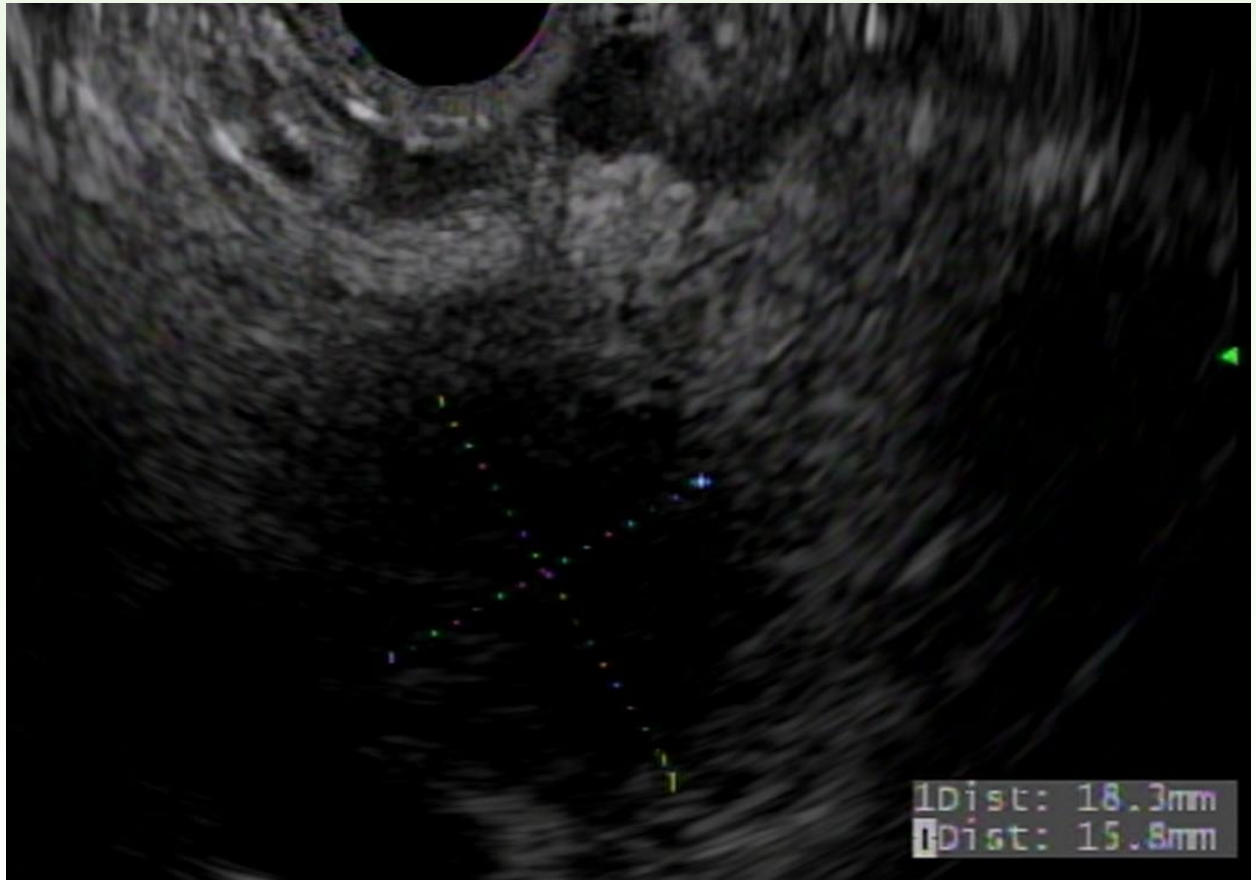

CEA: 2744 ↑
Amylase: 55
Cytology: negative

→ Mucinous cyst

Mucinous Cystic Neoplasm (MCN)

- Mucin-producing
- Female predominance (>98%)
- $4^{th}/5^{th}$ decade of life
- Body/Tail of pancreas (90%)
- NO communication with the PD
- Malignant potential
- Review of 90 resected MCNs: 10% had either high-grade dysplasia or pancreatic cancer
- Review of 344 resected MCNs: No HGD or cancer if <3 cm with normal serum CA 19-9 and no concerning features

Park et al. Pancreatology 2014; 14:131-6.
Goh et al. W J Surg 2006; 30:2236-45.

MCN

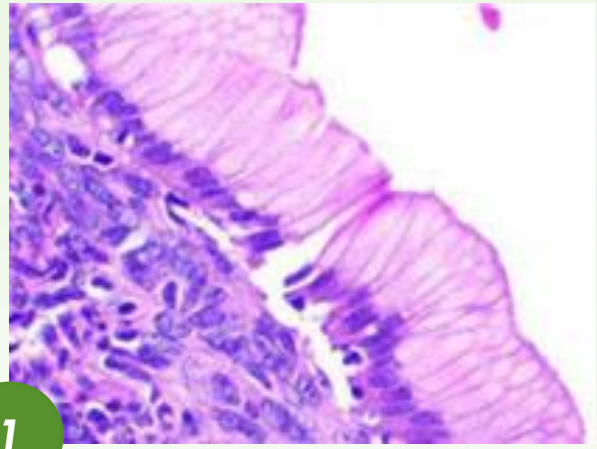

1

Columnar cells with underlying ovarian stroma

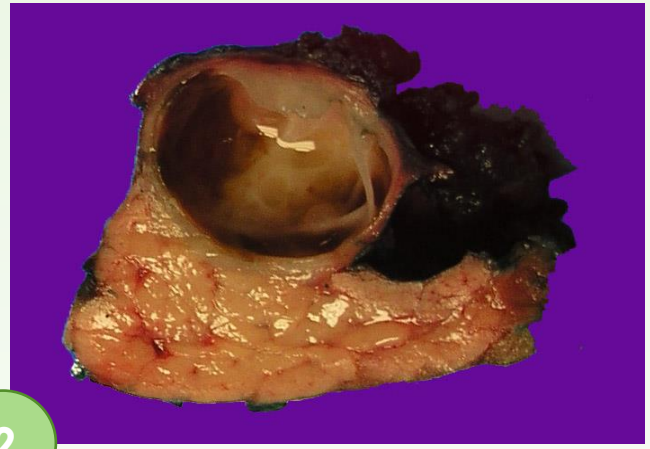

2

Larger components separated by thin septae / all surrounded by a thick fibrous capsule

3

FNA with aspirate of cells of uniform nuclear size

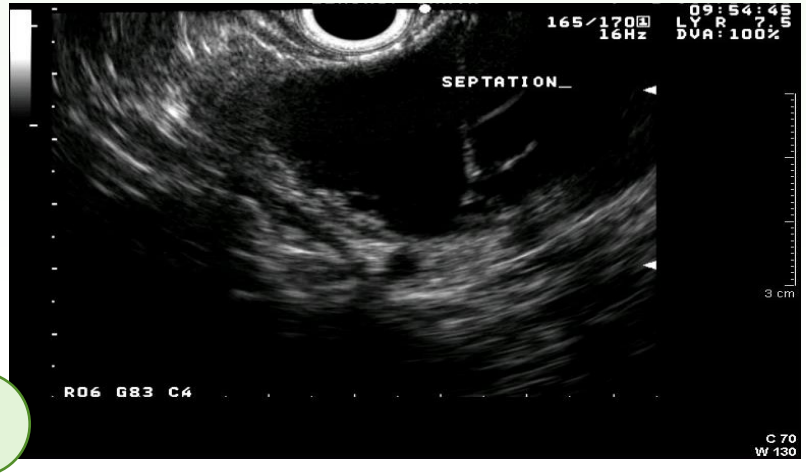

4

EUS image

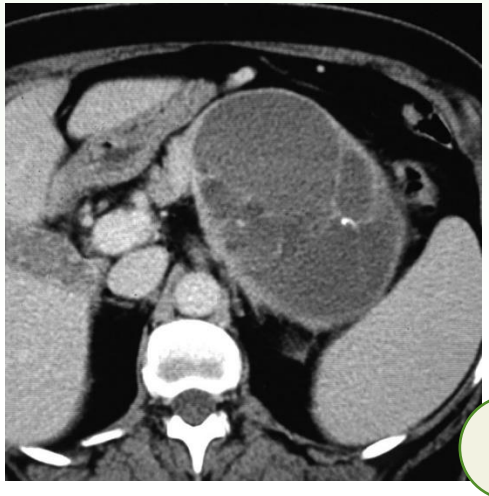

5

CT: large components, thin septae, thick fibrous capsule surrounding it all

Case #3 Continued

Seen at clinic, follow-up 2 weeks later.

He was experiencing ongoing pain and weight loss.

He was not able to go to work because of his symptoms.

Because of concerns for his symptoms, repeat CT was ordered.

CA 19-9: 7,734.0

CT A/P (1/11/23): Increase in size of cyst at neck of pancreas. Increased upstream pancreatic duct dilation.

EUS was repeated

EUS 1/17/23 Video

Practical Approach to Cysts: Imaging

- Main pancreatic duct diameter 5-9 mm
- Cyst ≥3 cm diameter
- Change in main PD caliber with upstream atrophy
- Associated solid mass
- Enhancing mural nodule < 5 mm
- Thick/Enhancing cyst walls
- Increased serum CA 19-9
- Cyst growth rate ≥ 5 mm / 2 years
- Lymphadenopathy

If seen on CT/MRI → EUS

If seen on EUS → FNA

Refer to tertiary care center

EUS with mural nodule: High Risk Feature

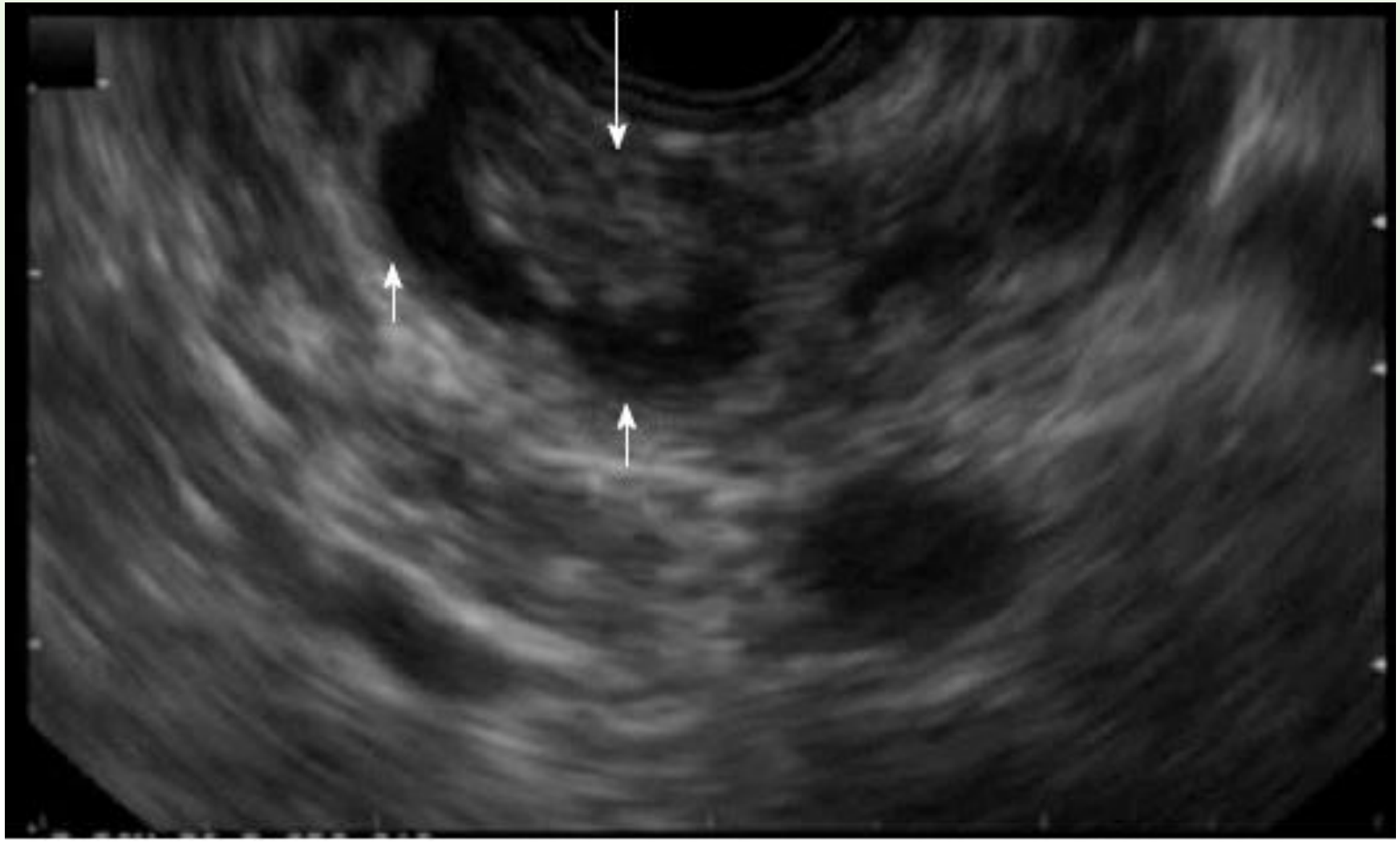

Solid Pseudopapillary Tumor

- Rare
- Women > Men (10:1)
- Usually young, 30s
- Presenting symptoms: Abdominal pain (60%), asymptomatic (40%)
- Single cysts, occur anywhere within the pancreas (usually body/tail)
- Refer to Multidisciplinary group for consideration of surgical resection
- Harbor a malignant potential
  - Vascular involvement 4.6%
  - Lymph node 1.6%
  - Distant metastases 7.7%
- 5-year survival rate is 95%
- 5-year recurrence rate in 10%

- 35 y/o Abdominal pain
- CT: ~5.5 cm mass in TOP

- EUS-FNB
- Solid pseudopapillary neoplasm

→ Surgical resection

- No recurrence on surveillance @ 2 years

Pancreas Cyst Referral



Cysts that do NOT require EUS or referral

- **Low risk patients:**
  - *No alarm signs/symptoms*
  - *No high risk features on imaging*
  - *No genetic mutation that would raise the risk of PC*
  - *No FHx of PC*
- **Relative certainty about the diagnosis**
- **BD-IPMN < 2 cm**
- **MCN < 2 cm**
- **Asymptomatic pseudocysts**
- **Non-surgical candidates?**

Cyst Surveillance

- Patients with presumed IPMNs and MCNs
- These cysts are present for years before the development of pancreatic cancer
- No prospective studies determining whether cyst surveillance alters mortality, BUT
- Surgery for high grade dysplasia or early pancreatic cancer have improved survival rates
- Surgically fit and willing
- Constantly reassess the utility of ongoing surveillance for each patient
- Psychological burden
- 82% felt surveillance reduced concerns of developing PC
- 94% felt that potential advantages of surveillance outweighed disadvantages

Overbeek et al. Pancreatology 2019; 19:1061-66.

CME/MOC QUESTION

- Which of the following pancreas cysts described by MRI on an otherwise healthy 50-year-old man do NOT require referral to a pancreatic specialty center?
  - A. 25 mm pancreas cyst with a connection to the main PD, which is not dilated
  - B. 8 mm pancreas cyst with a connection to the main PD, which is not dilated, in a patient with BRCA2 gene mutation
  - C. 10 mm pancreas cyst with a connection to the main PD in an asymptomatic patient
  - D. 12 mm pancreas cyst in a patient with recurrent acute pancreatitis
  - E. 9 mm pancreas cyst with a connection to the main PD with upstream atrophy of the parenchyma

CME/MOC ANSWER

A. 25 mm pancreas cyst with a connection to the main PD, which is not dilated

Larger cysts require further investigation and will need EUS (timing depends on guidelines)

B. 8 mm pancreas cyst with a connection to the main PD, which is not dilated, in a patient with BRCA2 gene mutation

Patients with a higher underlying risk of PC do not fall into the guidelines

C. 10 mm pancreas cyst with a connection to the main PD in an asymptomatic patient

D. 12 mm pancreas cyst in a patient with recurrent acute pancreatitis

The cyst may be contributing to RAP and also to eval the RAP this patient should undergo an EUS.

E. 9 mm pancreas cyst with a connection to the main PD with upstream atrophy of the parenchyma

Atrophy is a high risk radiographic feature that requires EUS to exclude underlying malignancy