

# NCSG Fellows Debate

Byung Soo Yoo, PGY-4

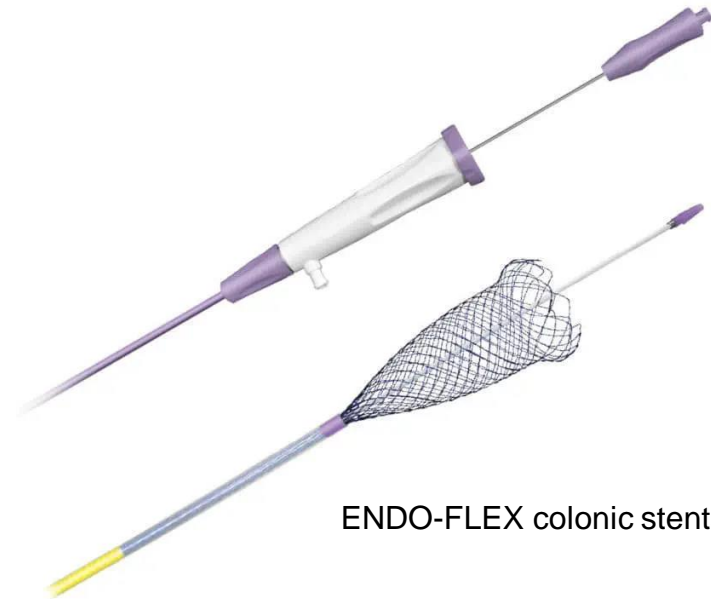



# Case – PRO STENT

- 62 yo female with history only notable for Turner's syndrome admitted to the hospital with recurrent sigmoid diverticulitis (two previous episodes) with imaging showing a mesocolic abscess.
- Imaging also suggests a large bowel obstruction from presumed sigmoid stricture in the region of the inflammation. The patient has had progressive abdominal pain and distention in the setting of no productive bowel movement in 5 days.
- Colorectal surgery is consulted and is requesting a colonic stent for benign sigmoid stricture related to diverticulitis. Surgical planning is otherwise unclear at this time.

# Colonic Stents – PRO STENT

- Self-Expandable Metallic Stents (SEMS)
- Through the scope (TTS)
- Varies in length and diameter
- Covered vs uncovered



ENDO-FLEX colonic stents (commercially available)

# Indications – PRO STENT

- Relief of symptoms
- Bridge to surgery
- Reduce risk of emergency surgery
- Converts 2-3 surgeries to single elective surgery
- Palliation
- Cost savings

# Stents are Effective in Malignant Strictures

- 1745 patients with malignant obstruction with colonic stents
  - 24 studies globally (RCTs, comparative studies)
  - Technical success – 96.2%
  - Clinical success – 92%
    - Colonic decompression and resolution of obstructive symptoms
  - Duration of study 106 days
    - 90.7% colonic patency at the end follow up

Watt AM et al. Self-expanding metallic stents for relieving malignant colorectal obstruction: a systematic review. *Ann Surg.* 2007;246(1):24-30.

# Stents are Effective in Benign Strictures

23 patients case series with benign colorectal obstruction

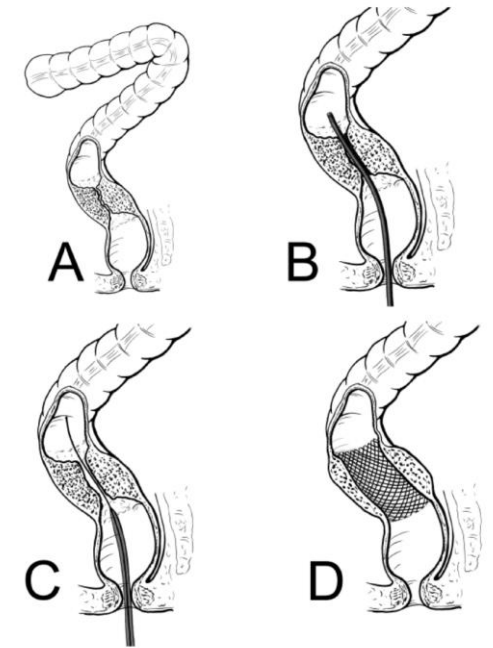
- Uncovered stents placed
- 95% obstructive symptom relief
- 84% converted to elective surgery
- 42% did not require stoma with elective surgery

Small AJ et al. Expandable metal stent placement for benign colorectal obstruction: outcomes for 23 cases. Surg Endosc. 2008 Feb;22(2):454-62.

# Stents are Effective in Benign Strictures

21 patient case series with sigmoid obstruction secondary to diverticulitis

- 100% technical success rate
- 100% obstructive symptom relief
- No mortality or major morbidity
- 80% converted to elective surgery
- No stoma creation (all primary anastomosis)



Lamazza A et al. Self-Expandable Metal Stents for Left Sided Colon Obstruction from Diverticulitis. A Single Center Retrospective Series. *Medicina (Kaunas)*. 2021;57(3):299.

# Stents as a Bridge to Elective Surgery

Meta-analysis of 5136 patients with malignant obstruction with stents as a bridge vs emergency surgery

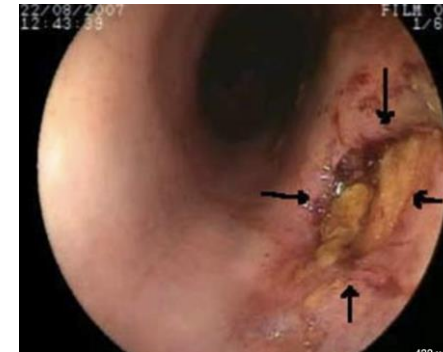
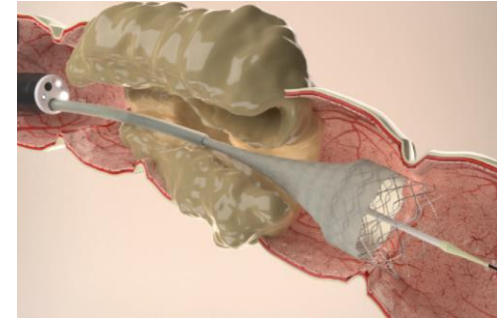
- Mortality - **0.9%** stent vs 5.2% surgery
- Primary anastomosis – **97.8%** stent vs 85.9% surgery
- Stoma creation – **2%** stent vs 11% surgery
- Post op complications – OR = 0.66, favoring stents over surgery

Kanaka S et al. Colonic stent as a bridge to surgery versus emergency resection for right-sided malignant large bowel obstruction: a meta-analysis. *Surg Endosc.* 2022;36(5):2760-2770.



# Complications of stents can be mitigated

- Stent migration decreased with use of uncovered stents
- Colonic perforation
- Recurrent obstruction
- Fistula formation



Ribeiro IB et al. Acute abdominal obstruction: Colon stent or emergency surgery? An evidence-based review. World J Gastrointest Endosc 2019; 11(3): 193-208

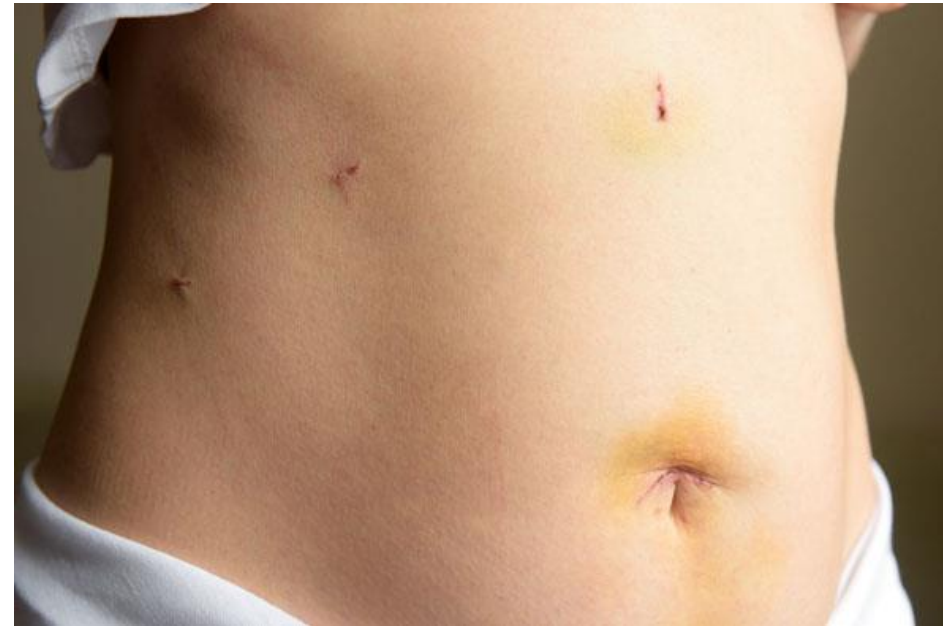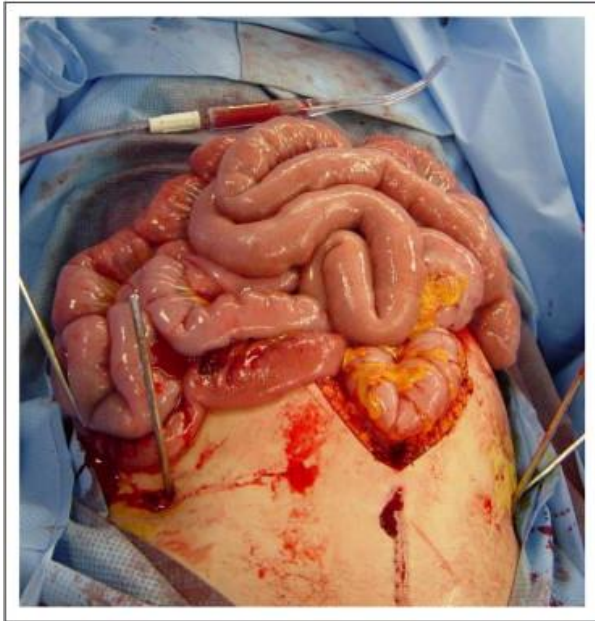
# Factors favoring stenting in our case

- Presumed sigmoid stricture
- Less invasive and costly
- Colonic perforation
  - 5-10% in acute diverticulitis (20% mortality)
    - Not including risk of perforation due to diverticular stricture and obstruction
  - 10% in malignancy related colon obstruction

Jamal Talabani et al. "Major increase in admission-and incidence rates of acute colonic diverticulitis." *International journal of colorectal disease* 29 (2014): 937-945.  
Yang, Kwan Mo, et al. "Oncologic outcome of colon cancer with perforation and obstruction." *BMC gastroenterology* 22.1 (2022): 1-7.

# Most importantly

**Reducing risk of emergency surgery and ultimately 3 operations without stenting**



# References

- Watt AM et al. Self-expanding metallic stents for relieving malignant colorectal obstruction: a systematic review. *Ann Surg.* 2007;246(1):24-30.
- Small AJ et al. Expandable metal stent placement for benign colorectal obstruction: outcomes for 23 cases. *Surg Endosc.* 2008 Feb;22(2):454-62.
- Lamazza A et al. Self-Expandable Metal Stents for Left Sided Colon Obstruction from Diverticulitis. A Single Center Retrospective Series. *Medicina (Kaunas).* 2021;57(3):299.
- Ribeiro IB et al. Acute abdominal obstruction: Colon stent or emergency surgery? An evidence-based review. *World J Gastrointest Endosc* 2019; 11(3): 193-208
- Kanaka S, Matsuda A, Yamada T, et al. Colonic stent as a bridge to surgery versus emergency resection for right-sided malignant large bowel obstruction: a meta-analysis. *Surg Endosc.* 2022;36(5):2760-2770. doi:10.1007/s00464-022-09071-7
- Jamal Talabani et al. "Major increase in admission-and incidence rates of acute colonic diverticulitis." *International journal of colorectal disease* 29 (2014): 937-945.
- Yang, Kwan Mo, et al. "Oncologic outcome of colon cancer with perforation and obstruction." *BMC gastroenterology* 22.1 (2022): 1-7.